

## Gallstone Liver Abscess Secondary to Gallbladder Perforation

Kamron Izadi, M.D., Franklin G. Moser, M.D., Katherine Haker, M.D., and Sean Satey

We present an unusual case of a pyogenic liver abscess containing gallstones caused by perforation from an inflamed gallbladder and spread of the infection into the liver. It was manifested by right upper quadrant abdominal pain, nausea, and vomiting for approximately 1 month. Ultrasound and computerized tomography demonstrated the findings however unappreciated, and the diagnosis was confirmed by laparoscopy. Open drainage and cholecystectomy were done, with good outcome. There have been very few reports in the literature of intrahepatic perforation of the gallbladder resulting in formation of hepatic abscess. The presentation, diagnosis, and management of liver abscesses, as well as the complications of acute cholecystitis are discussed.

### Introduction

While cholecystitis is a common cause of right upper quadrant abdominal pain and admission to the hospital for surgical reasons, it is significantly underreported when in conjunction with a hepatic abscess. Overall, perforation of the gallbladder from acute cholecystitis occurs in approximately 3-10% of patients. Usually, it manifests as acute free perforation, subacute perforation with pericholecystic abscess, or chronic perforation with cholecystoenteric fistula and, occasionally, gallstone ileus

[1]. We are reporting a rare case of a patient with cholecystitis, whose gallbladder perforated and a subsequent hepatic abscess developed that contained contents from the gallbladder, including a gallstone.

### Case Report

A 67-year-old Ethiopian woman with a prior medical history significant for hypertension and Type 2 diabetes mellitus presented to the emergency department with right upper quadrant abdominal pain, nausea, and vomiting for approximately one month. She had recently traveled to Ethiopia one month previously. She denies any history of fever, chills, chest pain, breathing difficulties, or peripheral edema. Approximately one year previously at an outside institution, she was worked up for similar symptoms and was told she had a benign liver lesion confirmed on biopsy, but was then lost to follow up. Abdominal examination at presentation revealed tenderness to deep palpation in the right upper quadrant, with a soft, non-distended abdomen.

---

Citation: Izadi K, Moser FG, Haker K, Satey S. Gallstone liver abscess secondary to gallbladder perforation. Radiology Case Reports. [Online] 2009;4:280.

Copyright: © 2009 The Authors. This is an open-access article distributed under the terms of the Creative Commons Attribution-NonCommercial-NoDerivs 2.5 License, which permits reproduction and distribution, provided the original work is properly cited. Commercial use and derivative works are not permitted.

Abbreviations: CT, computed tomography

Kamron Izadi, M.D. (Email: izadik@cshs.org), Franklin G. Moser, M.D., Katherine Haker, M.D., and Sean Satey are in the Department of Imaging, Cedars-Sinai Medical Center, Los Angeles, CA, United States of America.

Published: June 21, 2009

DOI: 10.2484/rcr.v4i2.280

## Gallstone Liver Abscess Secondary to Gallbladder Perforation

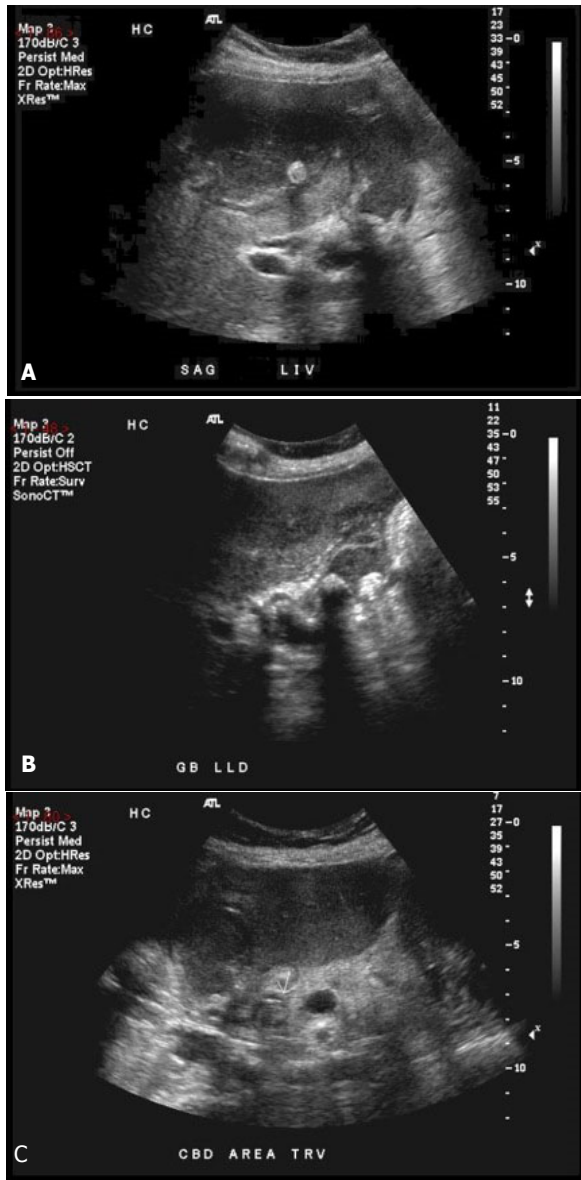


Figure 1. Sonography of a 67-year-old woman with gallstone liver abscess. **A**, The left hepatic lobe demonstrates hypoechoic abscess with focal echogenic gallstone internally. **B**, The gallbladder contains several echogenic calculi with posterior acoustic shadowing. **C**, There is an echogenic gallstone filling the common bile duct.

Ultrasound performed of the abdomen revealed a heterogeneous, 6.1 cm round mass in the right hepatic lobe containing a well circumscribed echogenic struc-

ture internally suggestive of a calculus (Fig. 1). The gallbladder was filled with stones and sludge and its wall measured 5 mm. The common bile duct was dilated to a measurement of 9 mm and contained calculi at its distal end.

An intravenous contrast enhanced CT of the abdomen and pelvis revealed a well circumscribed 4.2 x 3.3 cm structure with fluid attenuation suggestive of a liver abscess with apparent communication to a thick walled gallbladder (Fig. 2). The common bile duct is again markedly dilated. The calculi seen on the ultrasound was not appreciated on the CT.

Based on the radiological findings, the patient was diagnosed with complicated cholecystitis with perforation of the gallbladder and subsequent liver abscess formation. The patient was taken to surgery and an open laparotomy was done with cholecystectomy, liver abscess drainage, and intraoperative cholangiogram through the cystic duct. The cholangiogram demonstrated filling of the ductal system with a stone in the distal common bile duct. Proximal to the stone, the common duct was dilated to 10 mm.

## Discussion

The primary origin of acute cholecystitis is the persistent occlusion of the cystic duct by an impacted stone that causes increased gallbladder wall tension, epithelial injury, release of phospholipases, degradation of adjacent cell membranes, and intense inflammatory reaction [2]. In the adult population, 10% to 20% of the individuals are affected by asymptomatic gallstones [3]. Among them, 1% to 2% will suffer from acute cholecystitis in their lifetime [4]. Perforation of the gallbladder is a rare complication that occurs in 2% to 11% of all cases of acute cholecystitis [5], and it represents a surgical challenge because of the delay in recognition and treatment [6]. Gallbladder perforations are classified into 3 categories: type I includes patients with free perforation in the peritoneal cavity, type II includes those with localized perforation, and type III consists of cholecystoenteric fistulas [7]. A cholecystohepatic fistula secondary to acute cholecystitis with resulting pyogenic hepatic abscess formation has only been reported a few times in the literature.

With CT, a pyogenic liver abscess typically appears as a well-defined, round, hypodense mass with a

## Gallstone Liver Abscess Secondary to Gallbladder Perforation

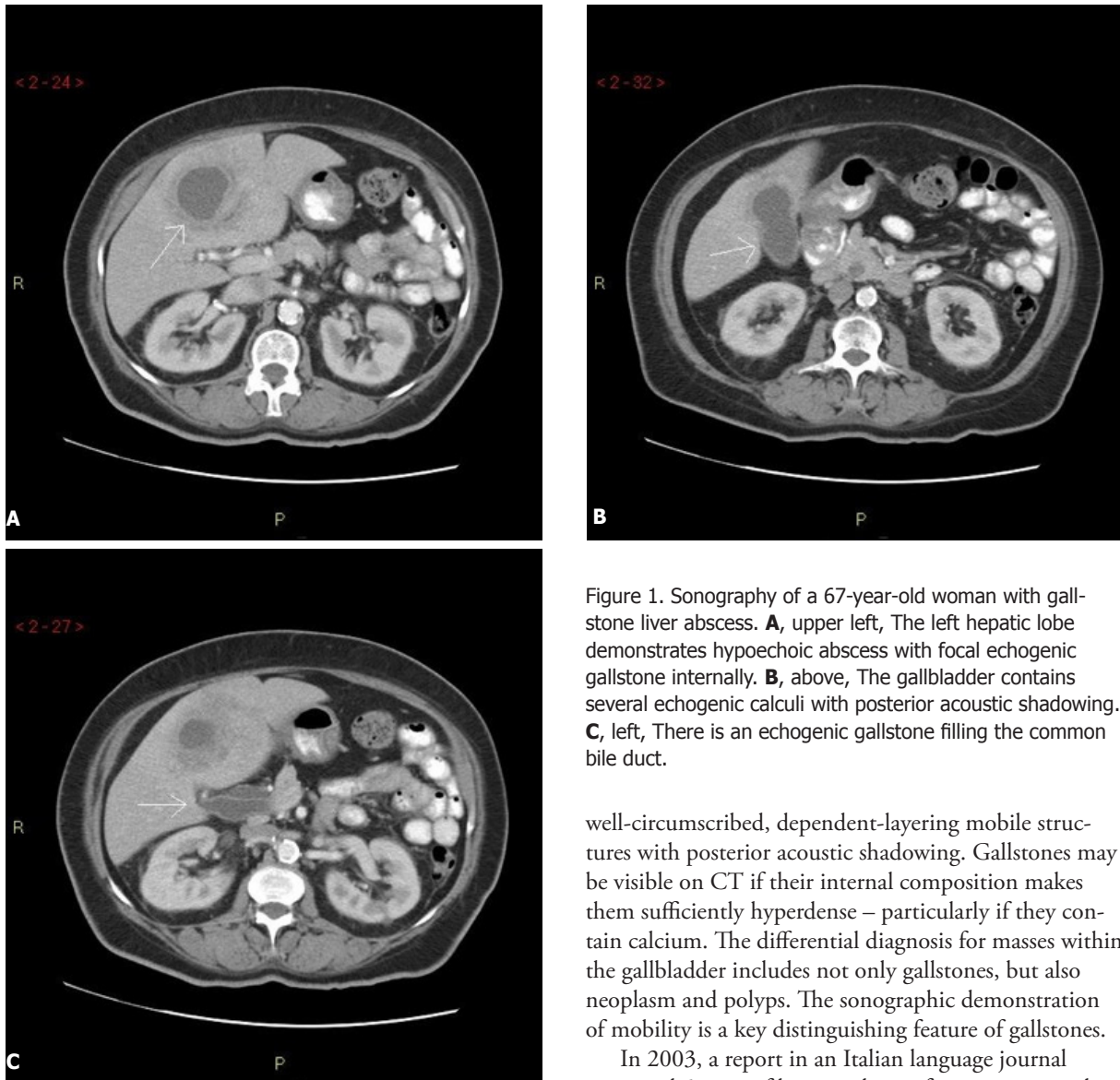


Figure 1. Sonography of a 67-year-old woman with gallstone liver abscess. **A**, upper left, The left hepatic lobe demonstrates hypoechoic abscess with focal echogenic gallstone internally. **B**, above, The gallbladder contains several echogenic calculi with posterior acoustic shadowing. **C**, left, There is an echogenic gallstone filling the common bile duct.

well-circumscribed, dependent-layering mobile structures with posterior acoustic shadowing. Gallstones may be visible on CT if their internal composition makes them sufficiently hyperdense – particularly if they contain calcium. The differential diagnosis for masses within the gallbladder includes not only gallstones, but also neoplasm and polyps. The sonographic demonstration of mobility is a key distinguishing feature of gallstones.

In 2003, a report in an Italian language journal presented 5 cases of hepatic abscess formation secondary to a perforated gallbladder in the setting of cholecystitis. In none of these was a large gallstone seen in the abscess. A common factor between all the patients in that study was the high length of time between onset of symptoms and diagnosis of hepatic abscess. In 4 out of the 5 patients, the length of times between the onset of symptoms and abscess diagnosis was 12, 30, 50, and 120 days respectively [8]. This fits with the patient at our institution, who had symptoms of abdominal pain, nausea, and vomiting for a full month prior to presentation.

central density that is between 0-45 Hounsfield units. The peripheral wall usually enhances with contrast administration and internal septa may be present. Small microabscesses may coalesce to form a larger abscess. At sonography, a pyogenic abscess usually appears round or ovoid with variable internal echogenicity. With color doppler, vascularity may be demonstrated if there is a thick-walled capsule. Differential diagnosis for an abscess may include neoplasm, amebic abscess, or hemorrhagic cysts. Sonography of gallstones typically reveals

## Gallstone Liver Abscess Secondary to Gallbladder Perforation

Bakalagos et al. in 1996 reported a case of cholecystohepatic fistula in a patient who presented with anemia, weight loss, and a palpable liver mass. The imaging was inconclusive and the pre-surgical diagnosis strongly favored a malignant process. A pyogenic liver abscess with gallstones was confirmed by laparoscopy. Similar to the prior report and our own patient, this patient had a smoldering clinical presentation, making the diagnosis more challenging [9].

The historical standard treatment of pyogenic liver abscess is surgical drainage with correction of the underlying process and systemic antibiotics [10]. Medical treatment with antibiotics alone has been reported, especially early in the course of the disease and when there is no surgically correctable etiological factor [11]. CT- or US-guided percutaneous drainage can be successful in poor-risk patients with solitary abscess, who do not have other indications for exploration [12].

Pyogenic hepatic abscess is a serious illness and can be a challenge to diagnose. Often, a high index of suspicion is required, especially in patients who present with symptoms and signs of a chronic illness, have diabetes mellitus, or are immunocompromised. The presence of a calculus within the hepatic collection should point towards the correct diagnosis. With appropriate treatment, the prognosis is favorable.

### References

1. Chen JJ, Lin HH, Chiu CT, Lin DY. Gallbladder perforation with intrahepatic abscess formation. *J Clin Ultrasound*. 1990 Jan;18(1):43-5. [PubMed]
2. Aljiffry M, Walsh M, Peltekian K, Molinari M. Type II gall bladder perforation with abdominal wall abscess in a cirrhotic patient: case report and review of the literature. *J Surg Educ*. 2008 Sep-Oct;65(5):367-71. [PubMed]
3. Gibney EJ. Asymptomatic gallstones. *Br J Surg*. 1990 Apr;77(4):368-72. [PubMed]
4. Friedman GD. Natural history of asymptomatic and symptomatic gallstones. *Am J Surg*. 1993 Apr;165(4):399-404. [PubMed]
5. Abu-Dalu J, Urca I. Acute cholecystitis with perforation into peritoneal cavity. *Arch Surg*. 1971 Feb;102(2):108-10. [PubMed]
6. Fletcher AG Jr, Ravdin IS. Perforation of the gallbladder. *Am J Surg*. 1951(81):178-85. [PubMed]
7. Niemeier DW. Acute free perforation of the gallbladder. *Am J Surg*. 1934(99):922-44.
8. Zerman G, Bonfiglio M, Borzellino G, et al. Liver abscess due to acute cholecystitis. Report of five cases. *Chir Ital*. 2003(2):195-8. [PubMed]
9. Bakalagos E, Melvin WS, Kirkpatrick R. Liver abscess secondary to intrahepatic perforation of the gallbladder, presenting as a liver mass. *Am J Gastroenterol*. 1996(8):1644-6. [PubMed]
10. Klatchko BA, Schwartz SI. Diagnostic and therapeutic approaches to pyogenic abscess of the liver. *Surg Gynecol Obstet*. 1989(168):332-6. [PubMed]
11. Stain SC, Yellin AE, Donovan AJ, Brien HW. Pyogenic liver abscess. Modern treatment. *Arch Surg*. 1991 Aug;126(8):991-6. [PubMed]
12. Mischinger HJ, Hauser H, Rabl H, et al. Pyogenic liver abscess: studies of therapy and analysis of risk factors. *World J Surg*. 1994 Nov-Dec;18(6):852-7; discussion 858. [PubMed]